

Recanalization of Total Arterial Occlusions with the Kensey Dynamic Angioplasty Catheter¹

The Kensey dynamic angioplasty catheter is a new device for recanalization of peripheral arterial occlusions. Twelve patients with segmental occlusions who were not considered candidates for conventional bypass surgery because of cardiovascular risk factors were studied. Four of the patients were treated in the operating room. Two had excellent primary results in limb salvage situations, and recanalization of an occluded femoropopliteal bypass graft was successful in another. Bilateral iliac recanalizations in the fourth patient were locally successful but did not prevent the patient's death from advanced ischemic disease. Eight patients were treated percutaneously. Initial recanalization was successful in seven. Four had early reocclusions and required amputation below the knee. One suffered distal embolization after recanalization of a 6-cm popliteal segment and underwent above-the-knee amputation. Long-term follow-up (7-18 months) in the other three patients with successful primary recanalizations has confirmed patency of the recanalized segments.

Index terms: Arteries, extremities, 92.7214 • Arteries, stenosis or obstruction, 92.7214 • Arteries, transluminal angioplasty, 92.128 • Catheters and catheterization, complications, 92.44 • Catheters and catheterization, technology • Embolism

Radiology 1989; 172:95-98

¹ From the Department of Radiological Sciences and Diagnostic Imaging, Shadyside Hospital, 5230 Centre Ave, Pittsburgh, PA 15232 (M.H.W., J.A.M.S., P.G., M.N.), and the Department of Mechanical Engineering, Carnegie-Mellon University, Pittsburgh (M.H.W., P.G., M.N.). Received July 15, 1988; revision requested September 22; revision received January 27, 1989; accepted February 3. Address reprint requests to M.H.W.

© RSNA, 1989

INTERVENTIONAL techniques have gained appeal in light of the abundance of patients with peripheral vascular disease (1). Balloon-and-wire technology has improved sufficiently to allow us to approach more distal lesions in the lower extremities. This improvement is a direct result of the balloon-and-wire profile technology developed for coronary circulation. Segmental arterial occlusions, which were heretofore treated only by vascular surgeons, are now being treated percutaneously. However, outflow limitations remain a significant problem in the treatment of patients with life-style limiting claudication and ischemic rest pain.

Interventional radiologists have realized that occluded arterial segments frequently permit passage of a wire to establish a "pilot hole." Further improvement in flow can be achieved with balloon angioplasty techniques. A few series of patients with occlusions that were treated with angioplasty have been reported (2-4). In our experience with 38 occlusions of superficial femoral and iliac artery segments, approximately 20% of the occlusions (eight of 38) could not be crossed with wires (M. H. Wholey et al, unpublished data, 1988). These patients are the focus of several devices undergoing clinical investigation.

Recanalization has been attempted recently with laser systems and with other devices. While the thermal-tip argon laser has been shown to be a useful adjunct to conventional percutaneous transluminal angioplasty (PTA) in iliac, femoral, and popliteal segments, its utility in smaller vessels and the issue of recurrent stenosis remain in question. In addition, PTA is ineffective in ablating calcified lesions, and the possibility of thermal injury is increased in this setting. The pulsed excimer laser appears to be more capable of establishing a pilot hole (5,6).

An alternative device, the Kensey dynamic angioplasty catheter (KDAC) (Theratek International, Miami), was evaluated at our institution in the treatment of segmental occlusions that could not be crossed with a wire. The KDAC was designed to pulverize atherosclerotic and thrombotic material sufficiently to allow their passage and clearance through the capillary network.

MATERIALS AND METHODS

The KDAC has a rotating semicircular cam at the distal end to selectively penetrate atherosclerotic material. The catheter tip is powered by a servo-controlled DC motor with manual speed control. The power is transmitted through a seven-strand drawn-steel cable inside the catheter sleeve. The KDAC is lubricated with perfusate by means of an injector system. The manufacturer has suggested a tip speed of 80,000 rpm and an injection rate of 20 mL/min. The device is manufactured from flexible polyurethane in sizes of 5-9 F. It may be introduced either by means of surgical cutdown or percutaneously through a sheath.

The KDAC exhibits some ability to selectively mobilize atherosclerotic tissue (7). In our laboratory, the catheter tip demonstrated that it could stay within the lumen of a plastic tube while boring through organic models made of different materials, including beef fat, cheese, and gelatin. The semicircular shape of the tip prevents impingement on arterial walls while it penetrates atherosclerotic material. Perfusate lubricates the drive cable within the catheter sleeve and dissipates heat from the catheter tip. The perfusate exits the catheter radially at the distal end. The mechanical interaction between the rotating tip and the atherosclerotic material and resistance by the rigidity of the catheter cable to the radial hydrodynamic forces generated at the tip influence the position of the catheter tip.

The catheter tip relies on a complex

Abbreviations: KDAC = Kensey dynamic angioplasty catheter, PTA = percutaneous transluminal angioplasty.

combination of fluid, dynamic, and mechanical effects to bore through clot material and to pulverize it. As a result, the debris should pass through the cardiovascular system without consequence. As the catheter tip rotates, a fluid vortex is created in which there is a pressure drop that induces a suction effect in the artery much like the action of an airplane propeller. In other words, the fluid dynamics resulting from the combined effects of perfusate flow and rotation of the tip in the fluid creates a vortex that distends the vessel lumen ahead of the actual catheter tip (Fig 1).

Our *in vitro* experience has shown that significant distal embolization occurs when total occlusions are penetrated with the KDAC. To prevent distal embolization, the catheter must recanalize the lumen enough so that the tip can emulsify particles to a size that can be easily filtered by the capillary system. The negative pressure effects cause particles to be drawn into the flow around the catheter tip and to remain in the region around the tip. Pulverization of particles depends on the length of time they recirculate around the tip. Because the size of emboli remains a central question in the performance of the KDAC, the length of recirculation time at the tip must be determined. Our current studies focus on determining how the length of recirculation time depends on the volume surrounding the tip and on tip speed and the feed rate of the catheter itself.

A clinical history was obtained and

physical examination and diagnostic arteriography performed on all patients before they entered the study. Routine cut-film angiography was performed to confirm clinical impressions.

Femoral arteries were chosen in each case for the catheter insertion site. In four patients, a surgical cutdown was performed; the remainder were treated by percutaneous means.

Six patients were treated for pregangrenous extremities. One patient was critically ill with occlusions of both iliac segments and the terminal aorta. Two patients in this group had occluded reversed-saphenous vein, femoropopliteal above-the-knee bypass grafts. All patients showed extremely poor outflow in the involved extremity on diagnostic arteriograms.

The procedure was explained to each patient and a witnessed informed consent obtained. Alternative forms of therapy were explained. Eleven of the 12 patients were not considered candidates for surgery because of associated cardiovascular risk factors. One patient chose to participate in the study because she opposed peripheral bypass surgery. Primary recanalization with the KDAC was carried out in all patients, and one patient required additional balloon angioplasty with a 6-mm-diameter, 4-cm-long balloon for residual stenoses (Fig 2). All patients were given a continuous infusion of heparin for 48 hours after the procedure to maintain the activated partial thromboplastin time at twice the control value.

Patient follow-up consisted of serial monitoring 24 hours after the procedure and clinical and noninvasive Doppler evaluations at 1-3-month intervals.

RESULTS

Recanalization was possible in all six patients in the limb salvage group. One patient had ipsilateral autonecrosis of three toes 7 months after the procedure and experienced extravasation of contrast medium at recanalization, causing the procedure to be immediately terminated. One day later, the patient again underwent arteriography and successful re-

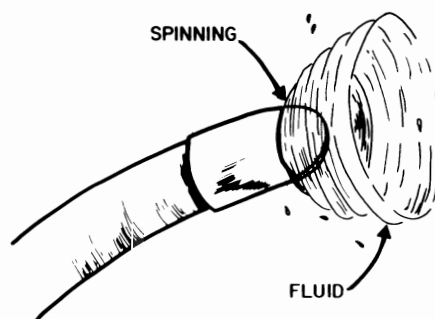


Figure 1. Illustration of the cam of the KDAC and the vortex created by the infusate.

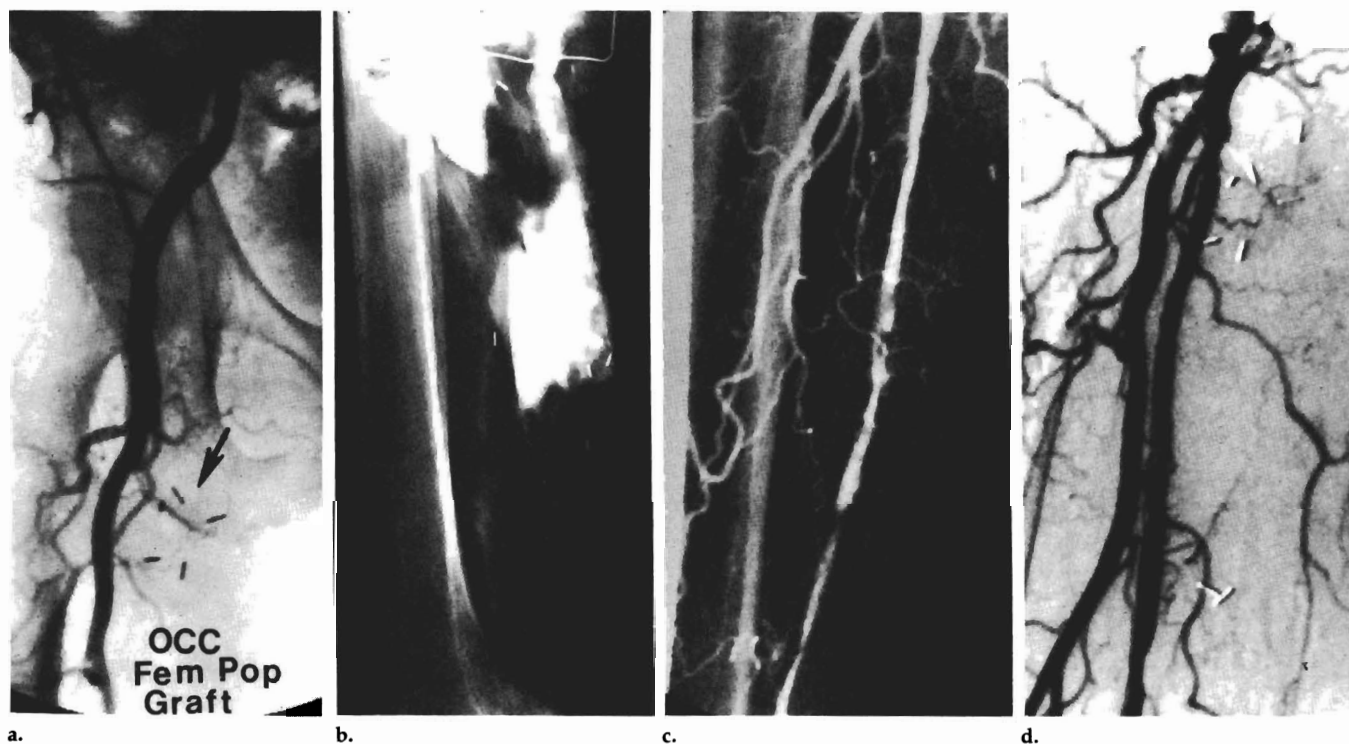


Figure 2. (a) Arteriogram shows occlusion (arrow) of the right superficial femoral artery at its origin. Reconstitution occurred at the popliteal artery level. Femoropopliteal graft is also occluded. (b) Extensive extravasation occurred after KDAC recanalization. (c) Follow-up femoral arteriogram 24 hours after recanalization now shows a patent lumen. Two isolated stenotic segments were subsequently dilated with conventional balloon angioplasty. (d) Note complete disappearance of extravasation 24 hours after recanalization and balloon angioplasty of residual stenotic segments. Satisfactory patency and dimensions through the previously occluded superficial femoral artery are seen.

canalization with the KDAC, eliminating the need for higher amputation; conventional PTA was required for two residual stenoses (Fig 2). One

patient was critically ill with occlusion of both iliac segments and the terminal portion of the aorta. Despite successful intraoperative recanaliza-

tion of the iliac arteries, the patient died of metabolic complications resulting from ischemia. Two patients with occlusions of reversed-saphenous vein, femoropopliteal bypasses underwent successful recanalization, but rethrombosis in one resulted in below-the-knee amputation. One patient required an above-the-knee amputation after reocclusion of a superficial femoral artery, with no significant runoff. One patient continues to do well clinically after recanalization of a popliteal artery segment 4 cm long, despite poor runoff.

In the group of six patients treated for claudication, recanalization was successful in all, but four required a surgical cutdown for insertion of the device. One patient, who refused surgery, required an above-the-knee amputation after the procedure because of embolization and failure to respond to local thrombolysis (Fig 3). The remaining five patients continue to do well at clinical follow-up (7-18 months). One patient underwent percutaneous insertion of the KDAC, with successful recanalization of an occluded 25-cm segment of the artificial femoral artery. The patient continues to do well clinically 18 months after the procedure (Fig 4).

DISCUSSION

The results of our experience with the KDAC technique in 12 patients with severe peripheral vascular disease varied from excellent in four patients to a disastrous complication in one. All patients had segmental arterial occlusions. Six were treated for limb salvage and had extremely poor outflow beyond the segmental occlusions. The six patients with preangrenous extremities did not show significant clinical improvement, and four required amputation.

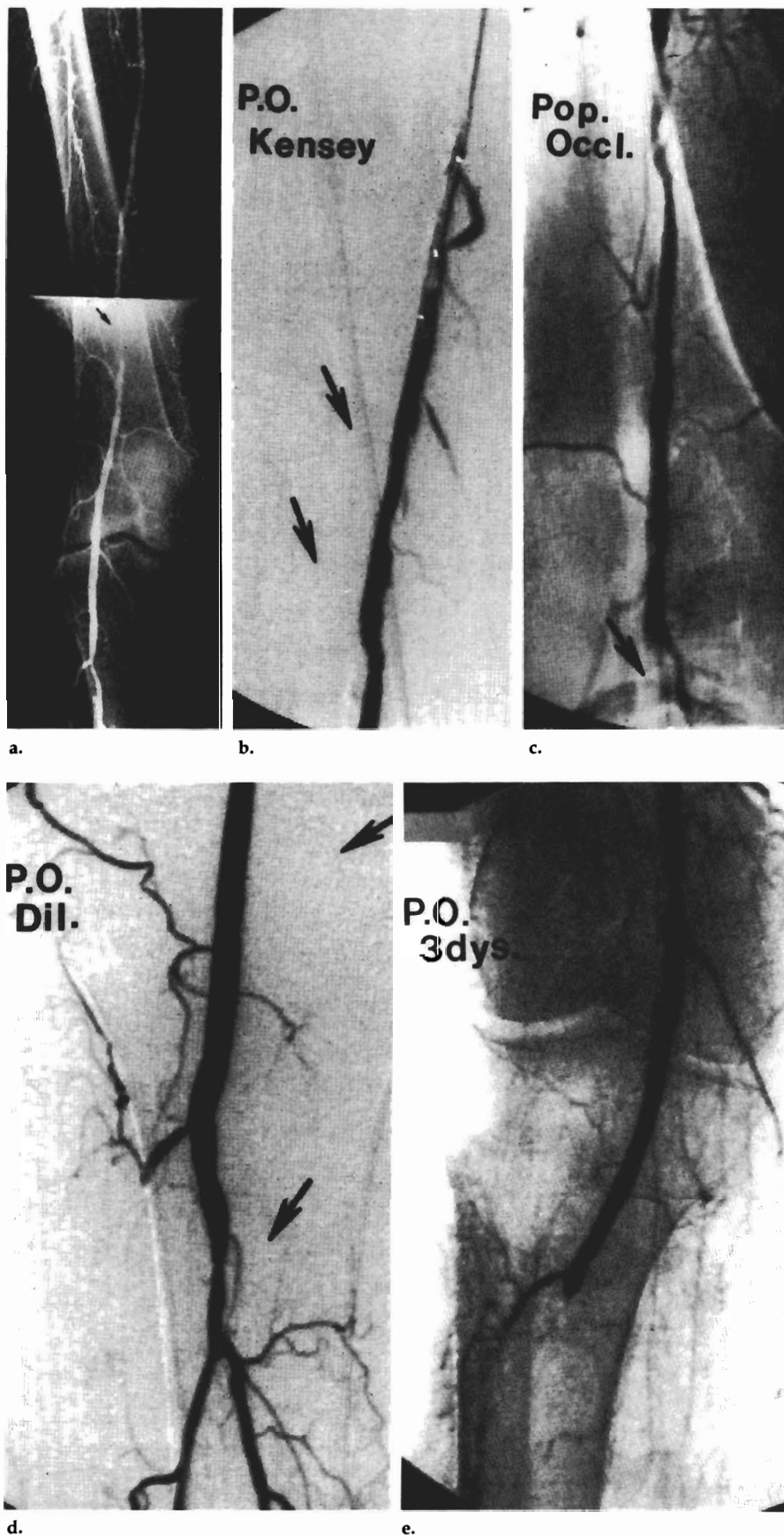


Figure 3. (a) Arteriogram shows occlusion (arrow) of a 6-cm segment in the right femoral artery near the distal adductor canal. (b) Effective recanalization of the obstructed segment (arrows) after KDAC pulverization. (c) Popliteal occlusion (arrow) resulting from apparent distal embolization after recanalization. (d) Reestablishment of popliteal-tibial outflow at the posterior tibial trunk after administration of 300,000 U of regional urokinase (1-hour infusion). Upper arrow indicates recanalization site. Lower arrow indicates reperfusion of posterior tibial trunk. Note occluded anterior tibial artery. (e) Three days after KDAC recanalization and urokinase infusion, posterior tibial trunk is reoccluded.

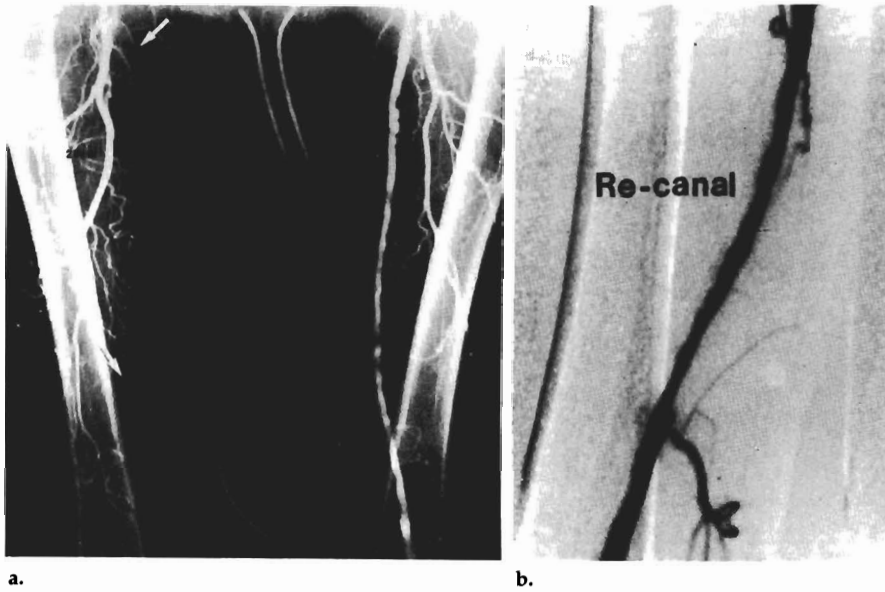


Figure 4. (a) Aortofemoral arteriogram demonstrates an occluded 25-cm segment of the right superficial femoral artery (arrows indicate length of obstruction). (b) Digital subtraction arteriogram shows effective recanalization of the obstructed superficial femoral artery after KDAC recanalization.

Excellent results were achieved in five of the six patients treated for claudication, three of whom underwent surgical cutdown for optimal exposure of the involved artery.

Percutaneous interventional techniques for total arterial occlusion continue to be evaluated at various centers around the country. Theoretically, the KDAC system pulverizes atheromatous material to a particulate size that is not considered clinically significant. However, the results obtained in our patient who experienced embolic complications contradict this theory. While the KDAC may have applications in peripheral vascular occlusive disease, conventional wisdom suggests that embolization of particulate matter of any size is potentially harmful. Depending on the bulk of disease (ie, the quantity of atheroma in the lesion) and the physical makeup of the occlusion, outflow vessels do not appear to tolerate the procedure well.

Although the KDAC did not present a significant problem with vessel perforation, in contrast to other devices, contrast material extravasation may occur that necessitates immediate termination of the procedure. In this regard, we did not experience any clinical deterioration in two patients, and in one patient (Fig 2) successful recanalization was achieved 24 hours after extravasation.

The question of long-term patency after vascular recanalization remains unanswered. Many factors contribute to recurrent disease. Balloon interventional procedures may result in intimal or medial damage with consequent excessive myointimal proliferation and subsequent recurrent stenosis (8,9). For that reason, interest in mechanical and laser devices has been stimulated in hopes that removal of plaque discourages regional recurrence of the atheromatous occlusion (10,11).

Our experience with the KDAC

suggests that the device is capable of recanalizing occluded arterial segments in the iliac, superficial femoral, and popliteal systems. However, reocclusion occurred frequently, especially in the group of patients treated for limb salvage in the presence of poor runoff. We are uncertain whether the optimal therapy for peripheral vascular and coronary occlusive disease will ultimately be atherectomy, rotational ablation, laser recanalization, or conventional balloon angioplasty. Further study may be warranted. ■

References

1. Pollner F. Peripheral angioplasty steps out. *Medical World News* 1987; 28:30-38.
2. Colapinto R, Stronell R, Johnston KW. Transluminal angioplasty of complete iliac obstructions. *AJR* 1985; 146:859-862.
3. Martin E, Fankuchen E. Angioplasty of femoral artery occlusion: comparison with surgery. *AJR* 1981; 137:915-919.
4. Lu C, Zarins C, Yang CF, Sotturrai V. Long segment arterial occlusion. *AJR* 1982; 138:119-122.
5. Diethrick EB, Timbadia E, Bahadir I, et al. Argon laser assisted peripheral angioplasty. *J Vasc Surg* 1988; 22:77-87.
6. Litvack F, Grundfest WS, Papaioannou T, et al. Role of laser and thermal ablation devices in the treatment of vascular diseases. *Am J Cardiol* 1988; 61:81G-86G.
7. Kensey K, Nash J, Abrahams C, Zarins CK. Recanalization of obstructive arteries with a flexible, rotating tip catheter. *Radiology* 1987; 165:387-389.
8. Hewes RC, White RI Jr, Murray RR, et al. Long-term results of superficial femoral artery angioplasty. *AJR* 1986; 146:1025-1029.
9. Johnston KW, Rae M, Hogg-Johnston SA, et al. Five year results of a prospective study of percutaneous transluminal angioplasty. *Ann Surg* 1987; 206:403-413.
10. Quigley MR, Bales JE, Kwaan HC, Cerullo LJ, Block S. Comparison of myointimal hyperplasia in laser-assisted and suture anastomosed arteries. *J Vasc Surg* 1986; 4:217-219.
11. Abela GS, Normann SJ, Cohen DM, et al. Laser recanalization of occluded atherosclerotic arteries in vivo and in vitro. *Circulation* 1985; 71:403-411.